



**DATE CLINICAL BACKGROUND & STUDY DETAILS**

4.7.26

**PATIENT**

Biscuit Araujo

**SPECIES**

Feline

**BREED**

DSH

**SEX**

MN

**AGE**

4.9.18

**WEIGHT**

12.2lbs

**INTERPRETED BY**

Maggie Machen Lamy,  
DVM, DACVIM  
(Cardiology)

**HOSPITAL NAME**

Perry Hall AH

**REFERRING VET**

Dr. Baer

**INVOICE**

47458

**History:** Grade 2/6 holosystolic cardiac murmur, left PMI. Asymptomatic. Assess prior to dental. History of feline asthma.

**Pertinent abnormal PE/Chem/CBC/UA Results:** Lab work pending.

**Current medications:** Since 2023- Apoquel 16mg ¼ tab SID, Azithromycin q3 days, Cerenia 24mg ¼ tab q3 days

**Blood Pressure:** 104, 104, 104, 100mmHg #3 cuff tail- sternal.

**Sedation used:** Not required to complete full diagnostic ultrasound.

**Pertinent previous ultrasound results:** No previous.

**STAT:** Not requested.

**Imaging performed by:** Stephanie Warga RDCS, RVT.

**ECHOCARDIOGRAM FINDINGS**

2D, m-mode, color flow and doppler imaging is available. The left ventricular wall is mildly hypertrophied. There is a mildly hyperechoic endocardium consistent with fibrosis and ventricular remodeling. Mild papillary muscle remodeling. The right ventricle is subjectively normal in size and morphology. There no left atrial enlargement present. No right atrial enlargement present. Normal RVOT velocity. Systolic anterior motion (SAM) of the mitral valve is present, with an elevated dynamic LVOT velocity. There is mild eccentric mitral regurgitation present secondary to SAM. No other significant valvular regurgitation is present. There is no pericardial effusion noted. No pleural effusion appreciated. No obvious cardiac tumors.

**CARDIAC CHART**

| FELINE CARDIAC PARAMETERS | BODY WEIGHT (kg) | HR (BPM)                        | IVSd (cm) (Moise, Pipers)                | LVIDd (cm) (Moise, Pipers) | LVWd (cm) (Moise, Pipers) | FS (%)         | EF (%)      |
|---------------------------|------------------|---------------------------------|--|----------------------------|---------------------------|----------------|-------------|
| <b>NORMAL PARAMETER</b>   | -----            | 150-240                         | 3.5-0.55                                 | <2 (mean 1.5)              | 3.5-0.55                  | 35-67          | 80-100      |
| <b>PATIENT</b>            | 5.5              | NM                              | 0.63                                     | 1.3                        | 0.63                      | 43             | 78          |
| FELINE CARDIAC PARAMETERS | LA/AO (Boon)     | LA/AO HEART BASE (Swe) (Abbott) | LA 2D short axis Base view (cm) (Abbott) |                            | LVOT VEL (m/s)            | RVOT VEL (m/s) | E max (m/s) |
| <b>NORMAL</b>             | <1.5             | <1.3                            | <1.2                                     |                            | <1.6                      | <1.3           | <0.9        |
| <b>PATIENT</b>            | NM               | 1.3                             | 1.3                                      |                            | 3.0                       | 1.5            | NM          |

Adapted from June Boon, Veterinary Echocardiography, 1998  
Abbott J & MacLean H JVIM 2006;20: 111-119, Moise et al. Am J Vet Res 47:1476, 1986. Pipers et al. Am J Vet Res 40:882, 1979.

### **INTERPRETATION OF THE FINDINGS & FURTHER RECOMMENDATIONS**

The diagnosis is hypertrophic obstructive cardiomyopathy (HOCM). This indicates LV thickening (mild in this case) with a dynamic LVOT obstruction (SAM) and secondary mitral regurgitation as the cause of the heart murmur. The hypertrophy and obstruction are both mild. There is no left atrial enlargement present, indicating the risk of spontaneous CHF and/or a thrombotic event is currently low. No additional issues are identified.

While no medications have been shown to definitively alter long term outcome at this stage of disease, atenolol is often initiated to decrease the outflow obstruction. Given the mild nature of the findings, this is not indicated at this time. *Regarding the newly available drug Felycin:* This medication has not been tested in cats with a significant obstruction (i.e. HOCM) and is not recommended in this case.

Long term prognosis is guarded for subclinical HOCM, with a great deal of variability in rate of progression. The REVEAL study showed that approximately 7% of asymptomatic cats with HOCM will develop CHF or a cardiogenic thrombus within 1 year, 20% within 5 years, and ~30% within 10 years. Close monitoring for progressive LA dilation going forward will help better predict long term outcome.

Monitor at home for any respiratory signs or blood clot events (neurologic change, paralysis, etc.).

Anesthetic risk is considered mild; however, judicious fluid administration is advised if needed with careful monitoring to screen for fluid overload. A reasonable protocol includes opioid/benzodiazepine premedication, propofol induction, isoflurane maintenance. Avoid ketamine, telazol, acepromazine and Dexdomitor. Additionally, drugs that stimulate heart rate should be avoided unless clinically necessary (glycopyrrolate, atropine).

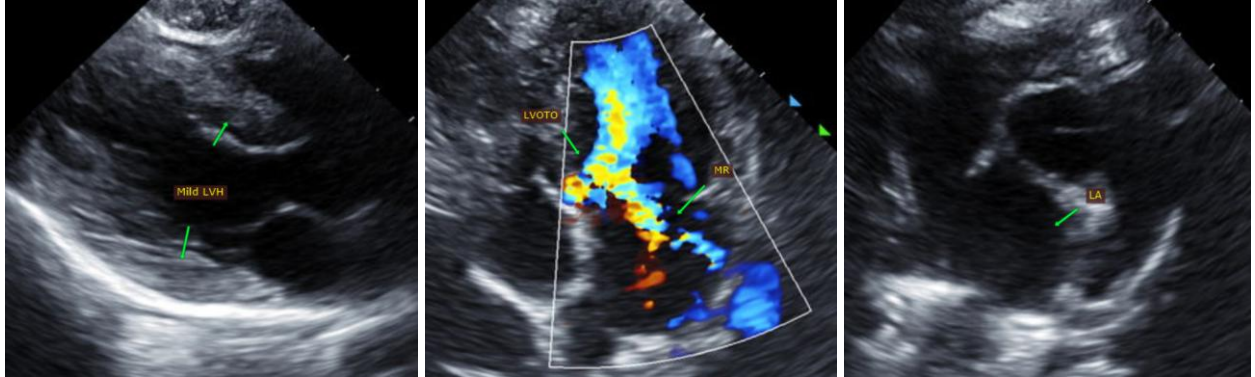
Risk for complication with steroid or fluid use typically follows LA dilation, which in this case is low. That said, any cat can experience acute intolerance and monitoring for this phenomenon is always advised (a change in RR/RE, particularly during the initiation phase).

### **PLAN**

Screening blood pressure and T4 are recommended every 6 months.

Recommend recheck echocardiogram in 6-12 months to assess for progression, sooner if clinical issues arise.

## IMAGES



**The information and recommendations provided are based on the images presented by the referring veterinarian. No evaluation can be communicated regarding pathology that was not visible in the image/video clips provided.**

Thank you for this referral. This report was generated using transcription software, and minor dictation errors may be present. If the clinical or image interpretation does not parallel your findings or if I can be of any further assistance, please contact me.

**Maggie Machen Lamy, DVM**  
**Diplomate of the American College of Veterinary Internal Medicine (Cardiology)**  
**info@sonopath.com**